

8 (4)
 15 (3) x (15) cooperative




2 (1) عن

(5) x (9)

1) Thy (3)

2) App (2)
 3) all
 4) 4


Principles



Cell A sm



Push up
Delivery
Min to visit

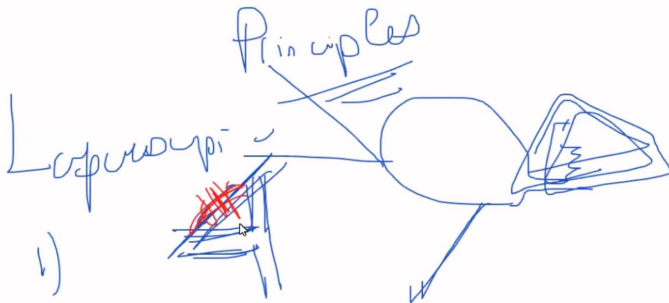


Case of thin IL

1) Rols go \rightarrow B U - U

2) \overline{EIN} :
 \overline{IEN} : chods

Cage of the IL 3) ~~Ag points~~
 1) Rols go \rightarrow B U - U
 2) ~~ELN~~ : chords
~~ALN~~ :
 SLN : 3) RL N :




Recently some surgeons
advise 1. CVS technique
[Critical view of soft tissue]
just the over 1/3 of GBA rep fronted back

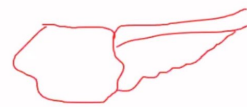
0/00
Lap ~ Pngli ~ 360
a k - 1 Png







Tax
 (Good view) in car
 at the Bus! Paid.
 Lan 2 in
 Apples
 ASD




Paintings
 Spk

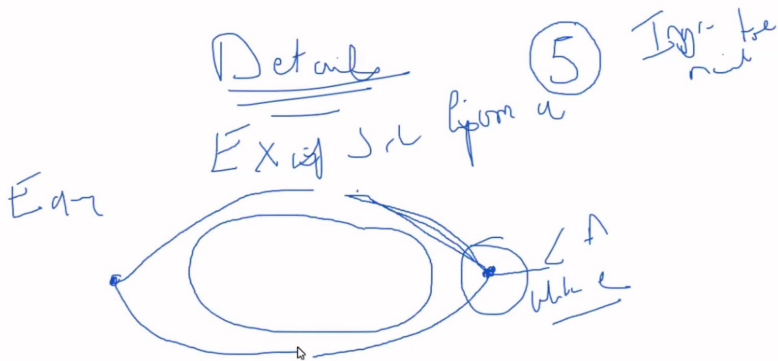





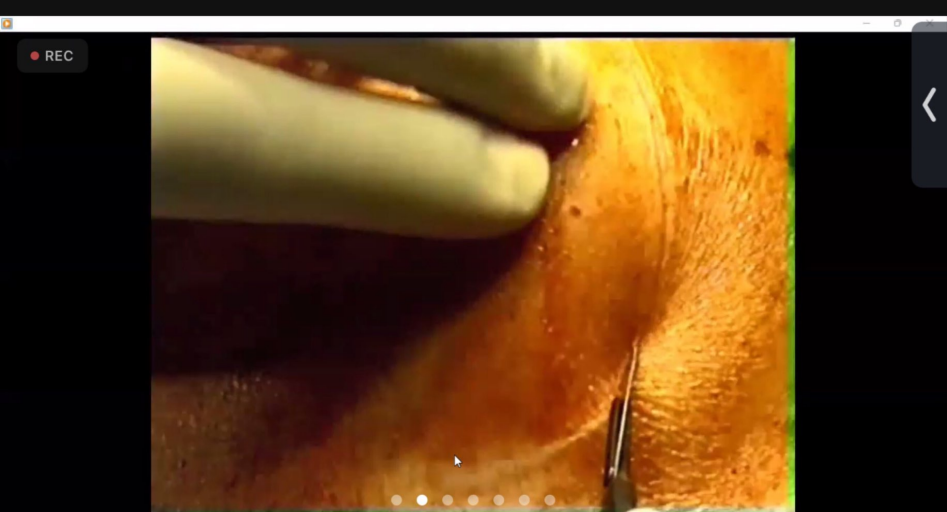



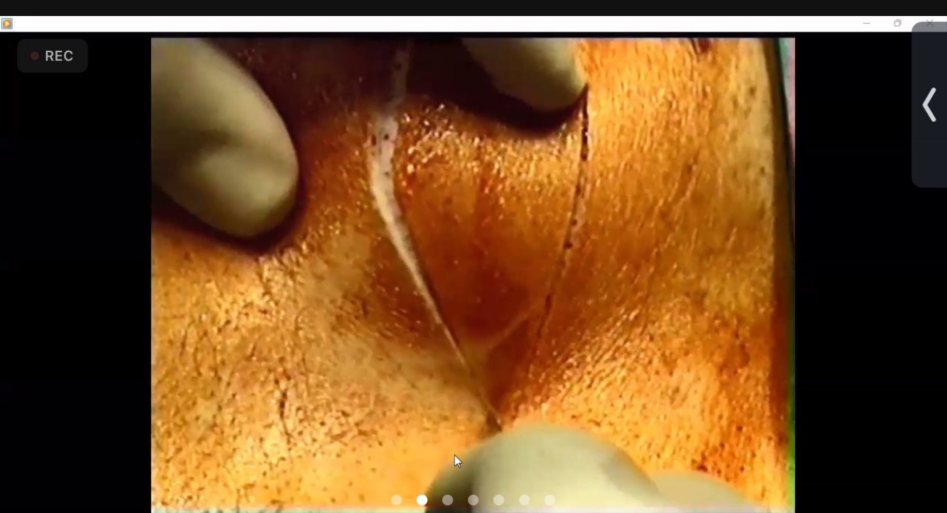




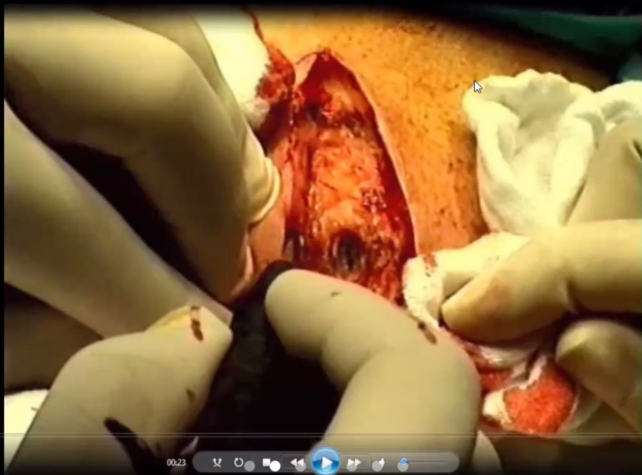


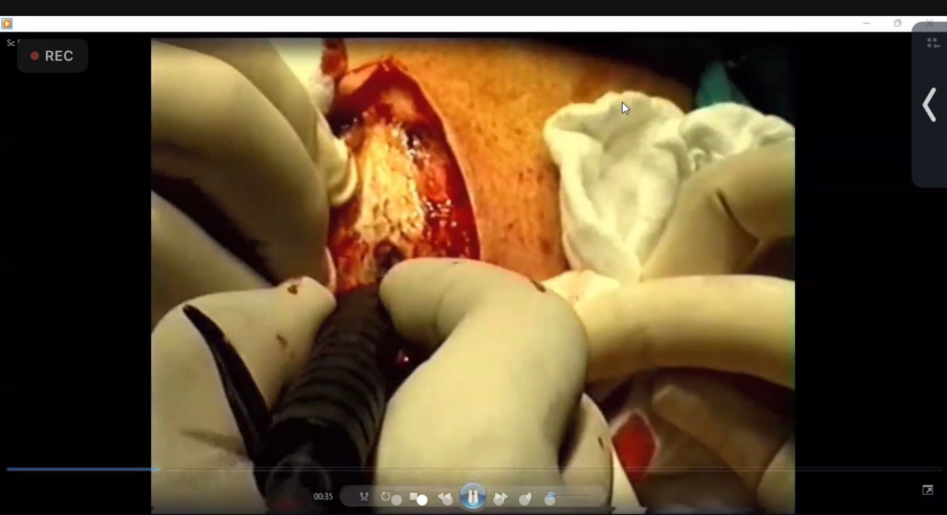


Scanned with CamScanner

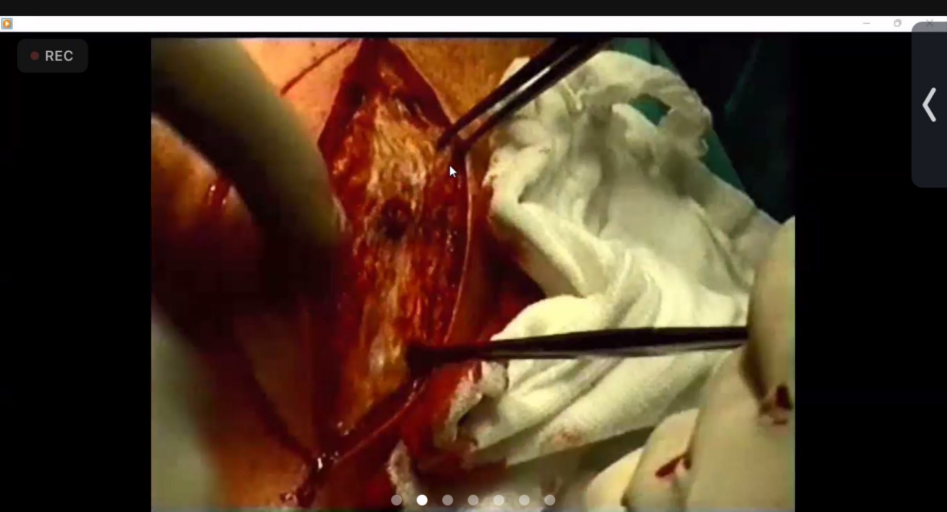


Scanned with CamScanner

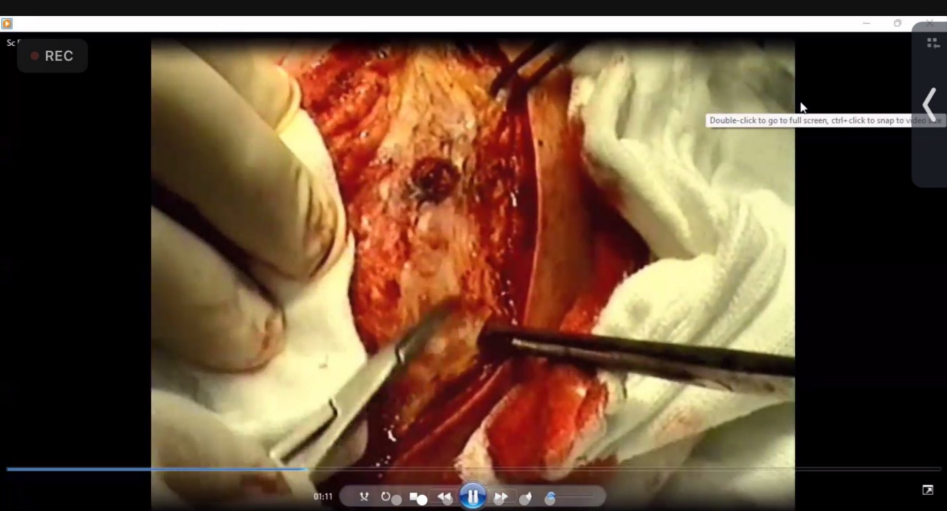




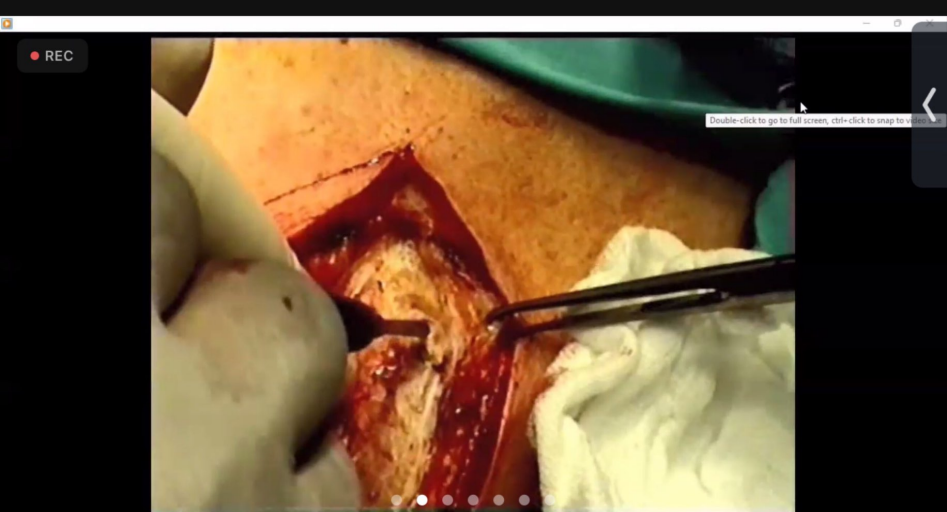Scanned with CamScanner



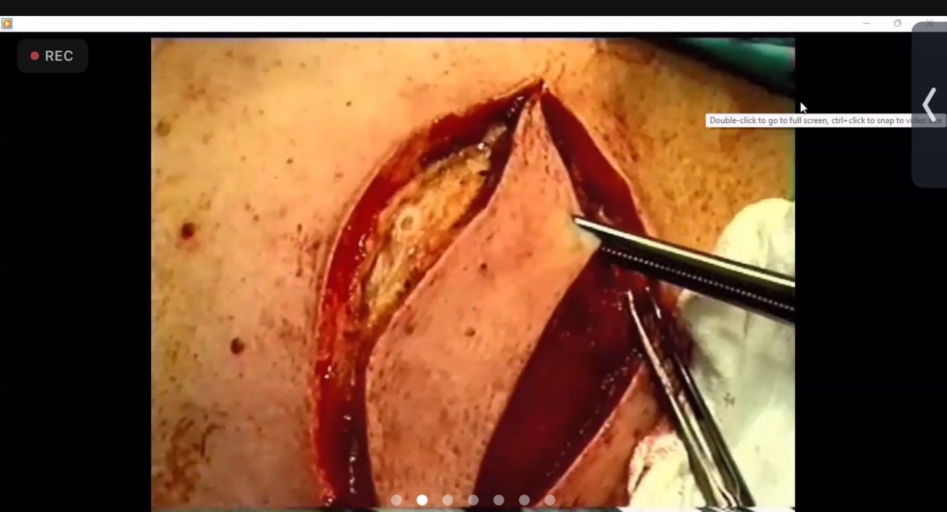
Scanned with CamScanner



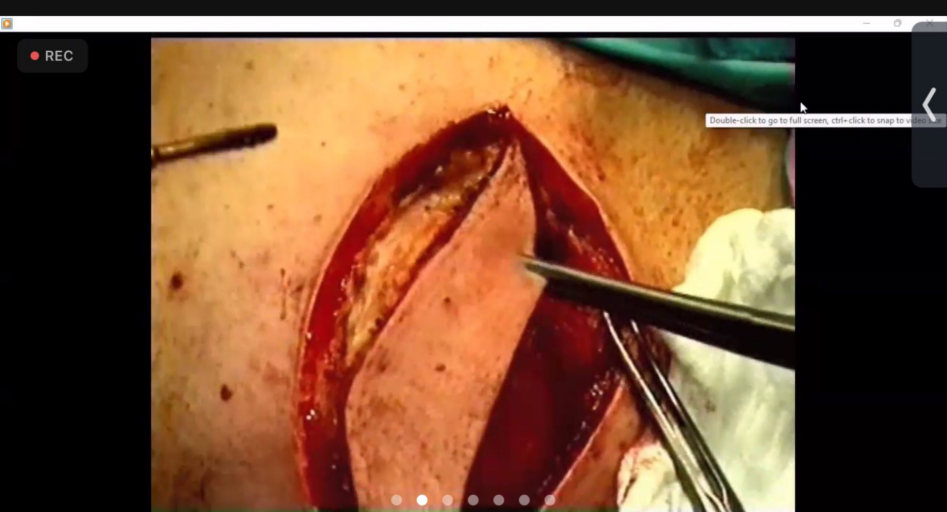
Scanned with CamScanner



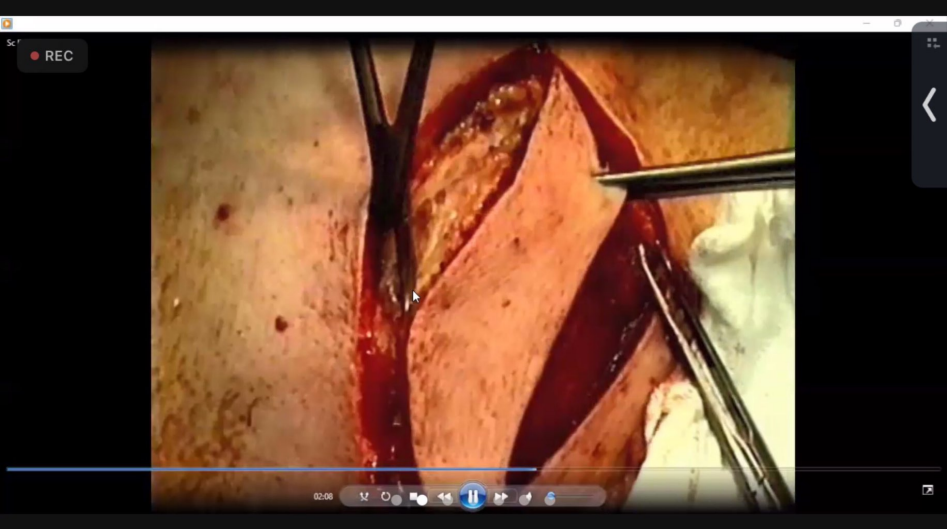
Scanned with CamScanner



Scanned with CamScanner



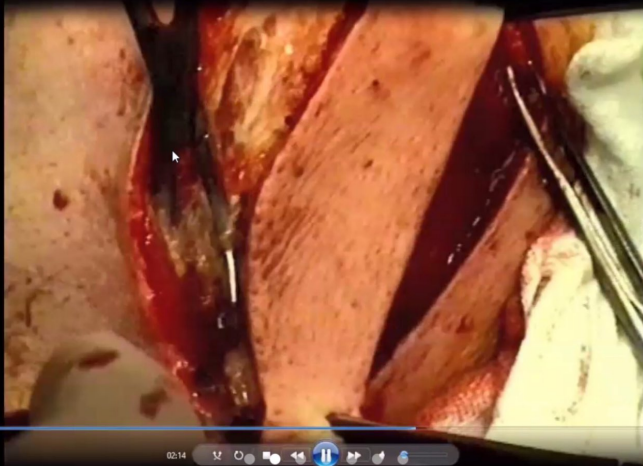Scanned with CamScanner



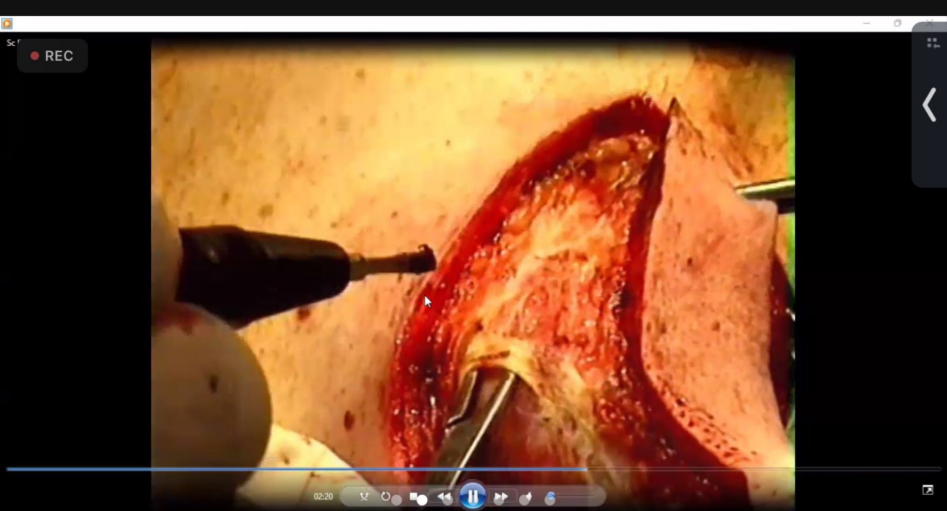Scanned with CamScanner

مریم وصفی left

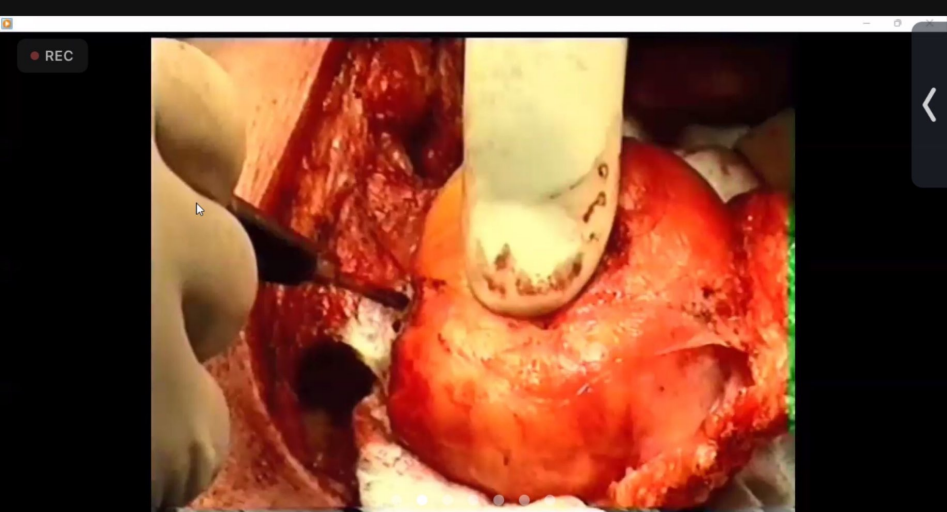
REC



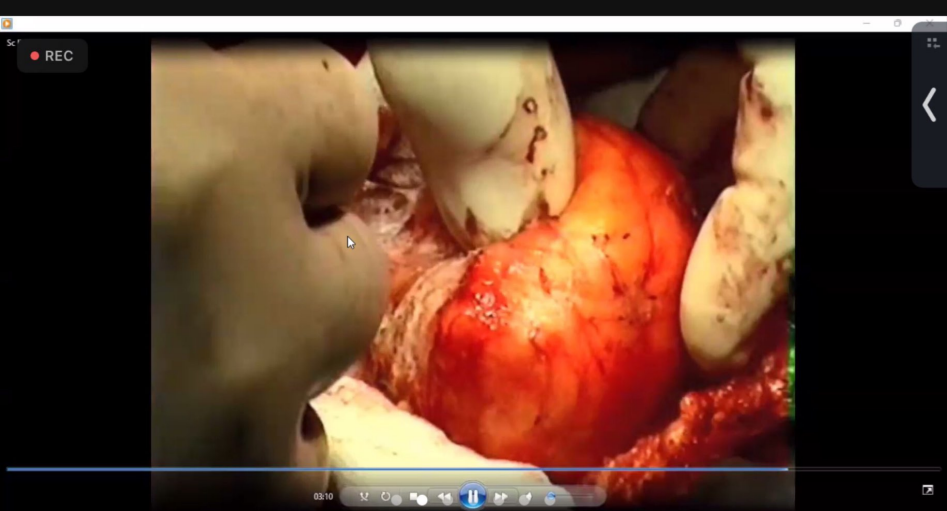
Scanned with CamScanner



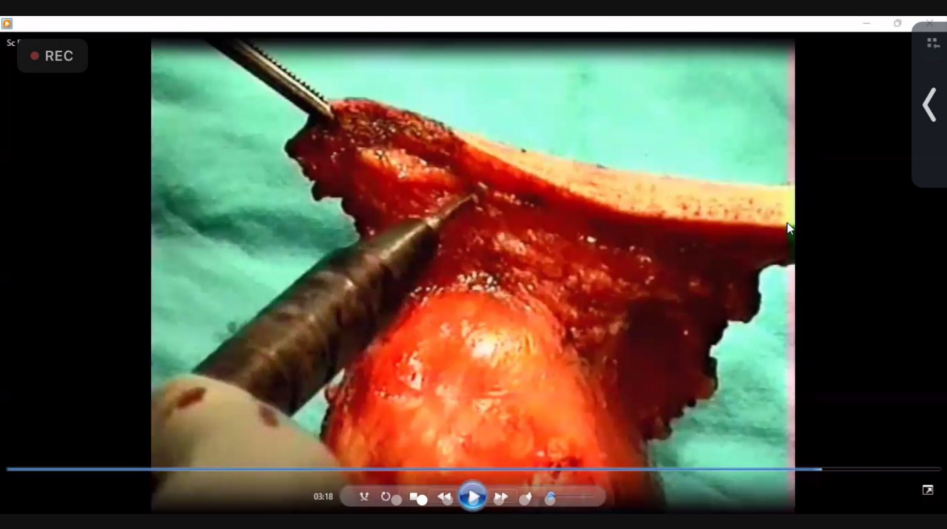
Scanned with CamScanner



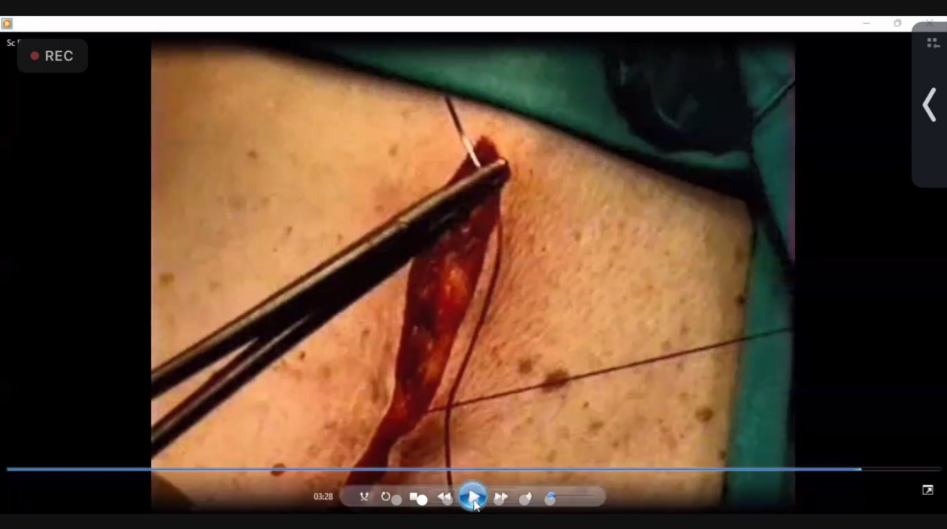Scanned with CamScanner



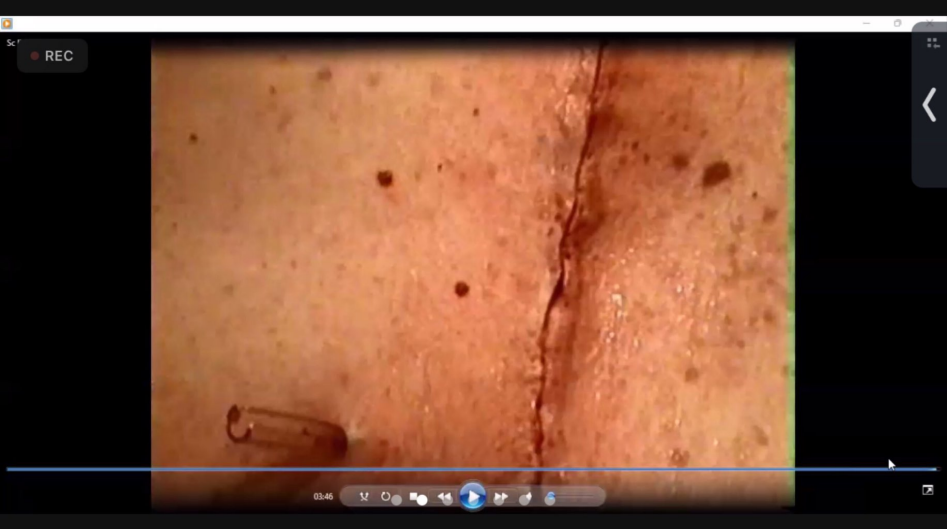Scanned with CamScanner



Scanned with CamScanner



Scanned with CamScanner



Scanned with CamScanner


REC

GIT Surgery.pdf

Operative 2021.pdf x

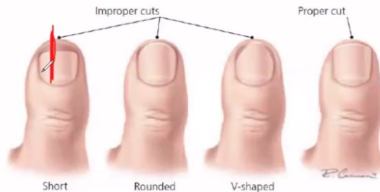


Sign In



Causes of ingrown toenail:

- Familial tendency
- Tight-fitting shoes or high heels
- Improper trimming of toenails (short and convexly).
- Chronic paronychia can cause a thickened or widened toenail and predispose to ingrown toe nail



Operative Surgery

11.00 x 8.50 in

Search 'Signature'

Export PDF

Edit PDF

Create PDF

Comment

Combine Files

Organize Pages

Delete, insert, extract and
rotate pages.

Try now

Convert, edit and e-sign PDF
forms & agreements

Free 7-Day Trial


REC

GIT Surgery.pdf

Operative 2021.pdf x

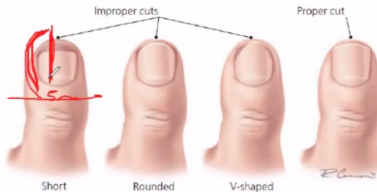


Sign In



Causes of ingrown toenail:

- Familial tendency
- Tight-fitting shoes or high heels
- Improper trimming of toenails (short and convexly).
- Chronic paronychia can cause a thickened or widened toenail and predispose to ingrown toe nail



Operative Surgery

11.00 x 8.50 in

Search 'Signature'

Export PDF

Edit PDF

Create PDF

Comment

Combine Files

Organize Pages

Delete, insert, extract and rotate pages.

[Try now](#)

Convert, edit and e-sign PDF forms & agreements

[Free 7-Day Trial](#)


REC

GIT Surgery.pdf

Operative 2021.pdf x

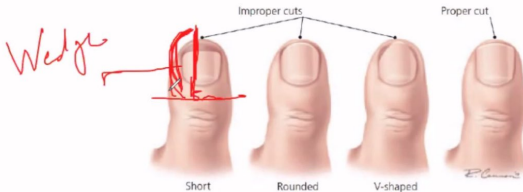


Sign In



Causes of ingrown toenail:

- Familial tendency
- Tight-fitting shoes or high heels
- Improper trimming of toenails (short and convexly).
- Chronic paronychia can cause a thickened or widened toenail and predispose to ingrown toe nail



Operative Surgery

11.00 x 8.50 in

Search 'Signature'

Export PDF

Edit PDF

Create PDF

Comment

Combine Files

Organize Pages

Delete, insert, extract and rotate pages.

Try now

Convert, edit and e-sign PDF forms & agreements

Free 7-Day Trial

REC


GIT Surgery.pdf

Operative 2021.pdf x

?

🔔

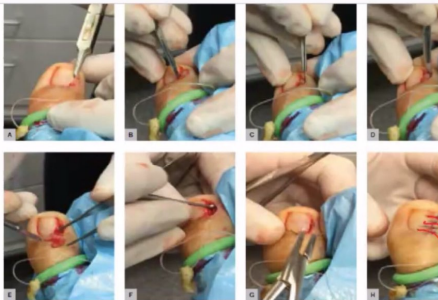
Sign In



25 / 90

100%

- through the skin by the side of the lesion.
- 5) Excise the wedge of tissues between the 2 incisions (including the nail & nail bed) leaving bear periostium
 - 6) Any remnants of the nail bed or germinal matrix should be curetted by the curettage spoon
 - 7) Remove the tourniquet
 - 8) Wound management:
 - a. Leave the wound open to heal by secondary intention if there was severe infection OR
 - b. The closed method, suturing the skin with the remaining nail with 2-3 interrupted non-absorbable sutures or applying Steri-Strips
 - 9) Finally the wound is dressed with a non-adherent dressing.



Search 'Signature'

- 📄 Export PDF
- 📄 Edit PDF
- 📄 Create PDF
- 💬 Comment
- 📄 Combine Files
- 📄 Organize Pages

Delete, insert, extract and rotate pages.

Try now

Convert, edit and e-sign PDF forms & agreements

Free 7-Day Trial

- intense pain due to pressure generated in tight space
- Discoloration of the nail: red or brown

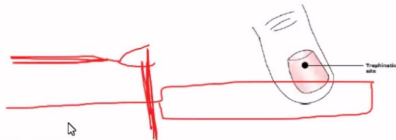
Management:

- Ice, limb elevation, anti-inflammatory drugs
- X-ray to exclude fracture

Surgery: **Trephination of the Fingernail**

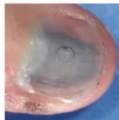- **L.A. is NOT required.**

- Surgery is done in the first 5 days because of the intense pain
- By the electrocautery or a **heated needle (its hub is held with an artery forceps)** a hole is created in the nail to drain th

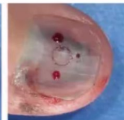

What advice would you give the patient

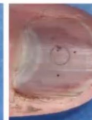- Wash with warm water with saline
- Postoperative Antibiotics & NSAIDs for 2-3 days




Pre-drilling



Post-drilling



4 days post-drillin



- intense pain due to pressure generated in tight space
- Discoloration of the nail: red or brown

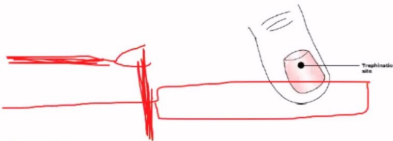
Management:

- Ice, limb elevation, anti-inflammatory drugs
- X-ray to exclude fracture

Surgery: Trephination of the Fingernail

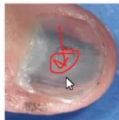• L.A. is NOT required.

- Surgery is done in the first 5 days because of the intense pain
- By the electrocautery or a heated needle (its hub is held with an artery forceps) a hole is created in the nail to drain th

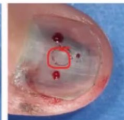

What advice would you give the patient

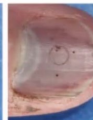- Wash with warm water with saline
- Postoperative Antibiotics & NSAIDs for 2-3 days



Pre-drilling



Post-drilling



4 days post-drillin

Search 'Signature'

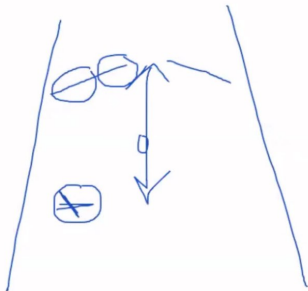
- Export PDF
- Edit PDF
- Create PDF
- Comment
- Combine Files
- Organize Pages

Delete, insert, extract and rotate pages.

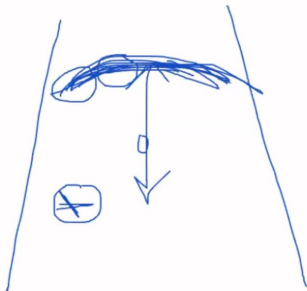
Try now

Convert, edit and e-sign PDF forms & agreements


Free 7-Day Trial



gastrecty



gastrecty




REC

GIT Surgery.pdf

Operative 2021.pdf x



Sign In



Classification & Types of abdominal incisions

According to their relation to the underlying muscles

1) Muscle splitting incisions:

- McBurney Grid-iron incision
- Lanz incision

2) Muscle reflecting incisions: Paramedian incisions.

3) Muscle cutting incisions:

- Kocher's (Subcostal incision) "See cholecystectomy"
- Chevron (Roof-Top) incision.
- Lumbar incision for simple nephrectomy.
- Rutherford-Morrison incision.

According to their shape:

1. Vertical (Midline & Paramedian incisions)
2. Transverse (Lanz incision & Pfannenstiel incision).
3. Oblique incisions (Kocher's incision, McBurney's incision & Rutherford-Morrison incision).
4. Sometimes combination as in emergency or Mercedes
5. Laparoscopic incisions



Pulse.

Operative Surgery
By Dr. H.R.

1) Vertical Incisions

11.00 x 8.50 in

Search 'Signature'

Export PDF

Edit PDF

Create PDF

Comment

Combine Files

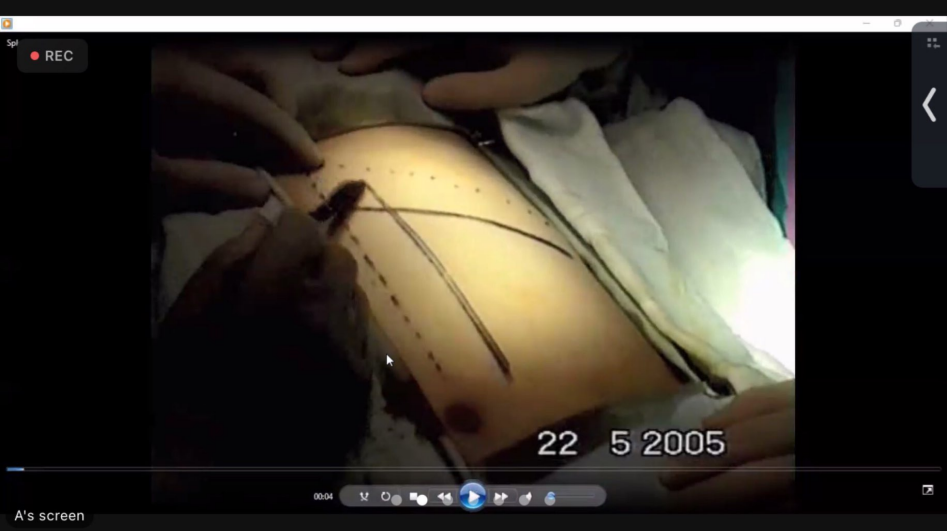Organize Pages

Delete, insert, extract and
rotate pages.

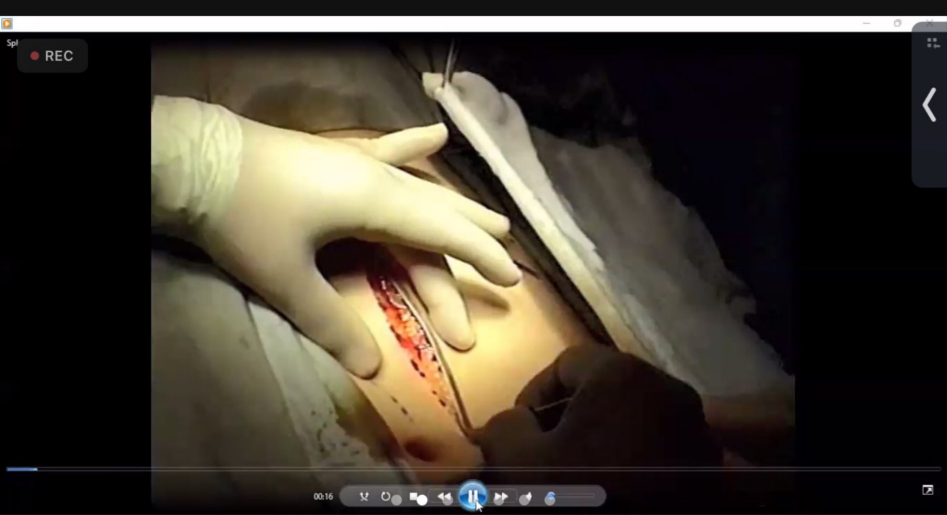Try now

Convert, edit and e-sign PDF
forms & agreements

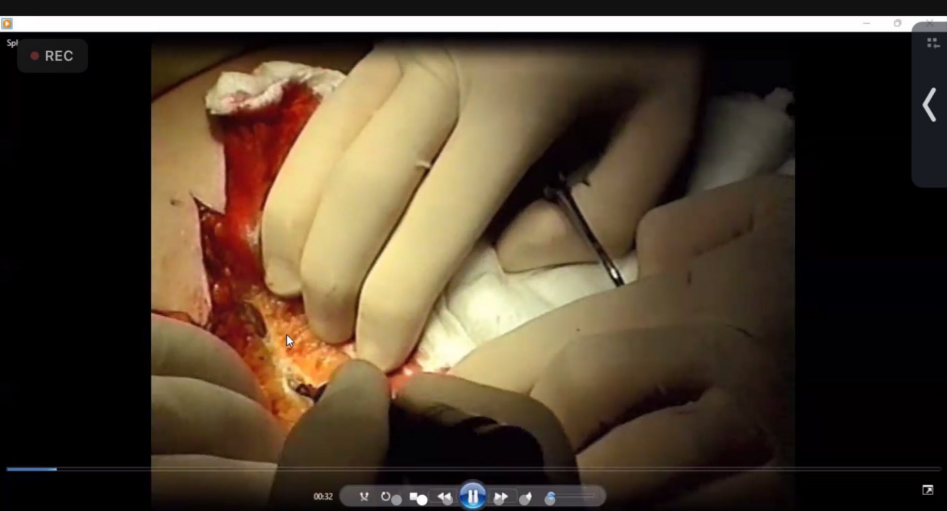Free 7-Day Trial



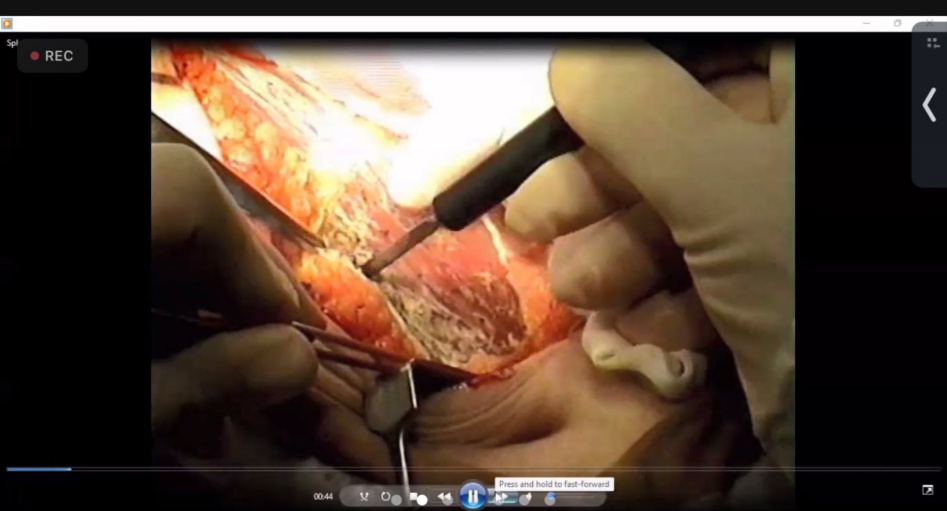Scanned with CamScanner



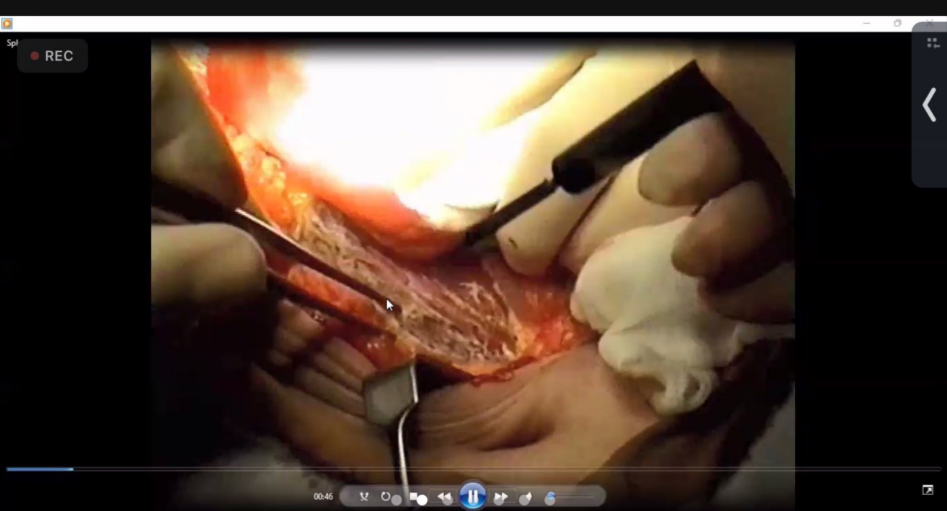
Scanned with CamScanner



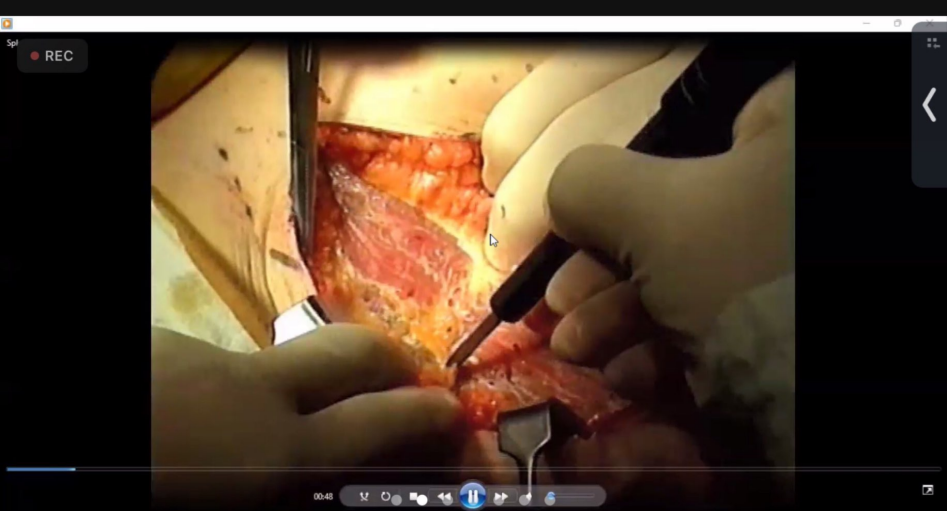
Scanned with CamScanner



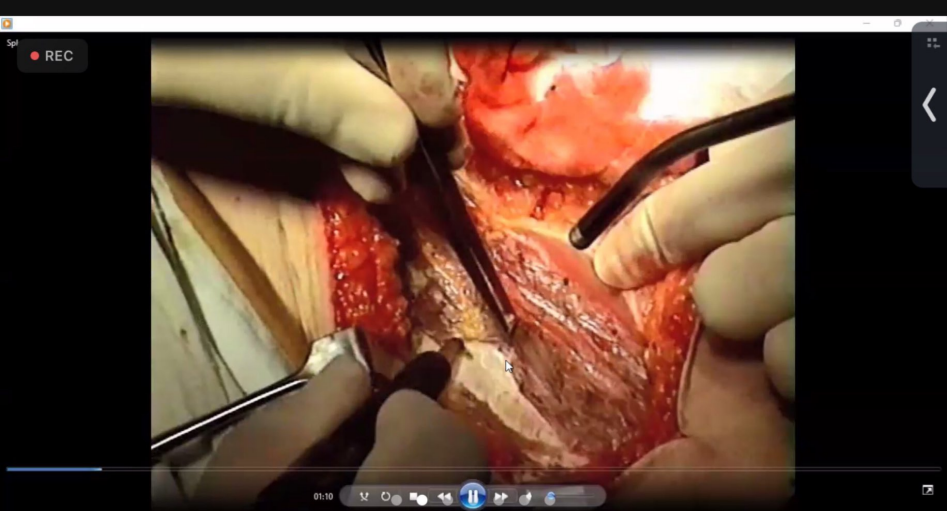
Scanned with CamScanner



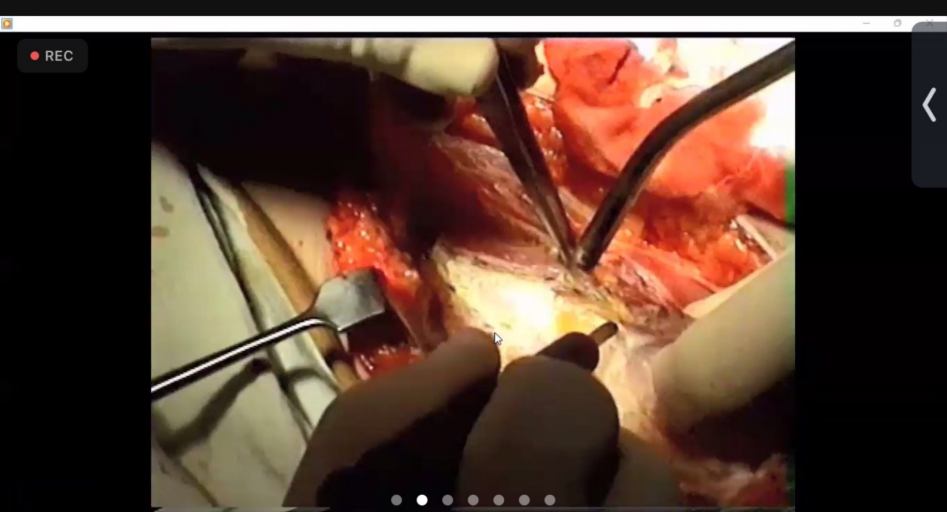
Scanned with CamScanner




Scanned with CamScanner



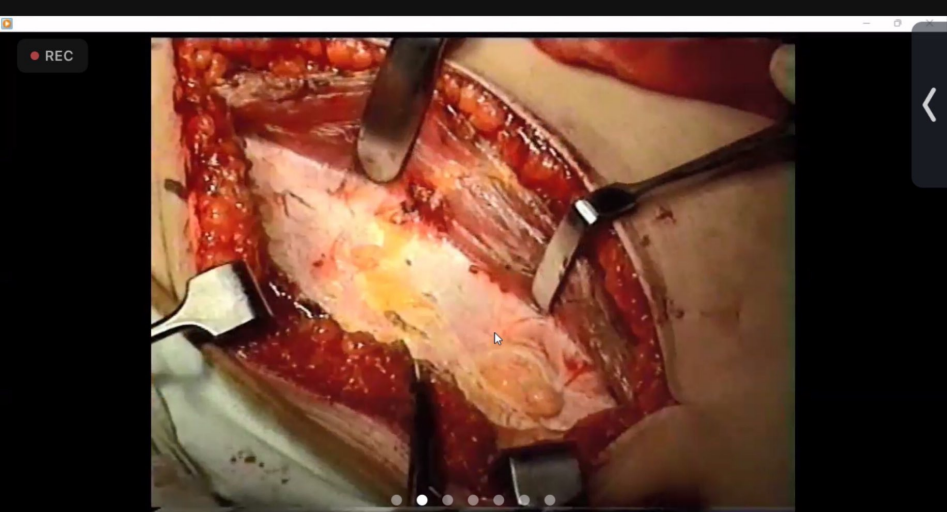
Scanned with CamScanner



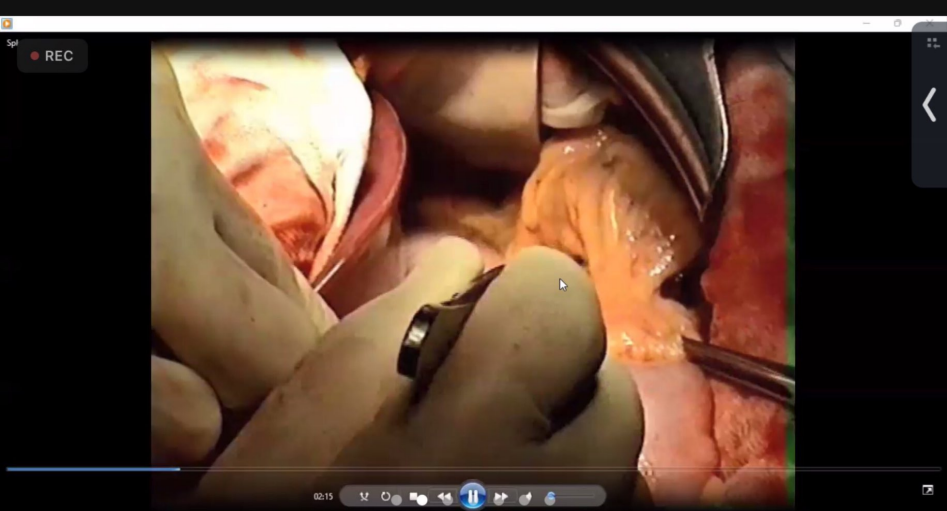Scanned with CamScanner



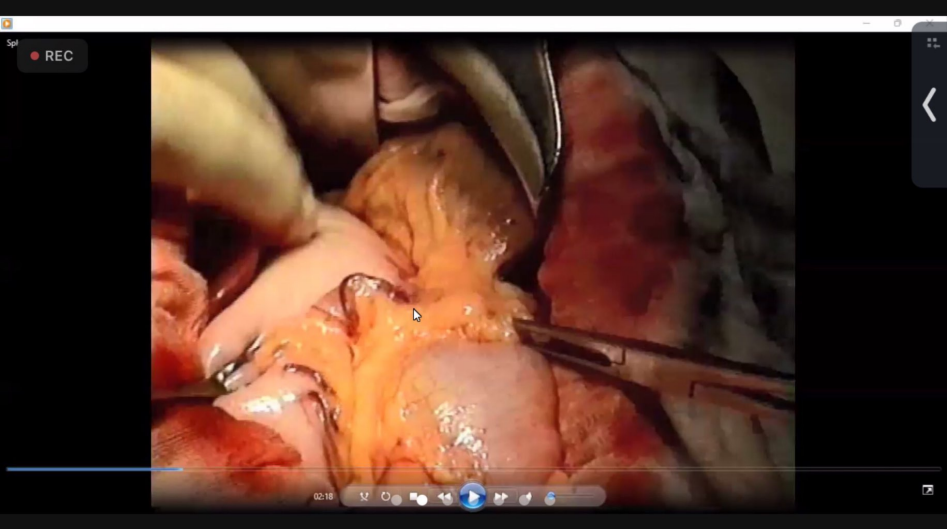
Scanned with CamScanner



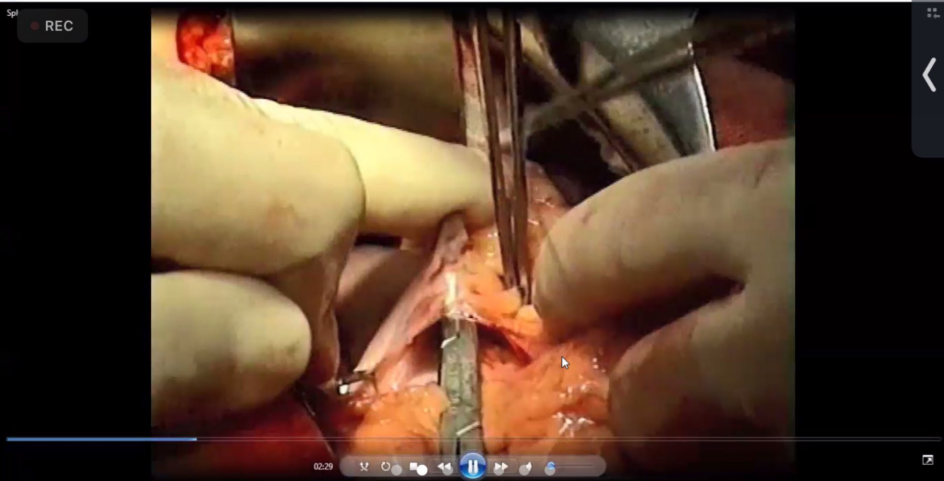
Scanned with CamScanner



Scanned with CamScanner



Scanned with CamScanner



REC


GIT Surgery.pdf

Operative 2021.pdf x

?

🔔

Sign In



Classification & Types of abdominal incisions



According to their relation to the underlying muscles

1) Muscle splitting incisions:

- McBurney Grid-iron incision
- Lanz incision

2) Muscle reflecting incisions: Paramedian incisions.

3) Muscle cutting incisions:

- Kocher's (Subcostal incision) "See cholecystectomy"
- Chevron (Roof-Top) incision.
- Lumbar incision for simple nephrectomy.
- Rutherford-Morrison incision.

According to their shape:

1. Vertical (Midline & Paramedian incisions)
2. Transverse (Lanz incision & Pfannenstiel incision).
3. Oblique incisions (Kocher's incision, McBurney's incision & Rutherford-Morrison incision).
4. Sometimes combination as in emergency or Mercedes
5. Laparoscopic incisions



Pulse.

Operative Surgery
By Dr. H.R.

1) Vertical Incisions

11.00 x 8.50 in

Search 'Signature'

- Export PDF
- Edit PDF
- Create PDF
- Comment
- Combine Files
- Organize Pages

Delete, insert, extract and rotate pages.

Try now

Convert, edit and e-sign PDF forms & agreements

Free 7-Day Trial

REC


GIT Surgery.pdf

Operative 2021.pdf x

?

🔔

Sign In



Classification & Types of abdominal incisions

According to their relation to the underlying muscles

1) Muscle splitting incisions:

- McBurney Grid-iron incision
- Lanz incision

2) Muscle reflecting incisions: Paramedian incisions.

3) Muscle cutting incisions:

- Kocher's (Subcostal incision) "See cholecystectomy"
- Chevron (Roof-Top) incision.
- Lumbar incision for simple nephrectomy.
- Rutherford-Morrison incision.

According to their shape:

1. Vertical (Midline & Paramedian incisions)
2. Transverse (Lanz incision & Pfannenstiel incision).
3. Oblique incisions (Kocher's incision, McBurney's incision & Rutherford-Morrison incision).
4. Sometimes combination as in emergency or Mercedes
5. Laparoscopic incisions



Pulse.

Operative Surgery
By Dr. H.R.

1) Vertical Incisions

11.00 x 8.50 in

Search 'Signature'

Export PDF

Edit PDF

Create PDF

Comment

Combine Files

Organize Pages

Delete, insert, extract and
rotate pages.

Try now

Convert, edit and e-sign PDF
forms & agreements

Free 7-Day Trial